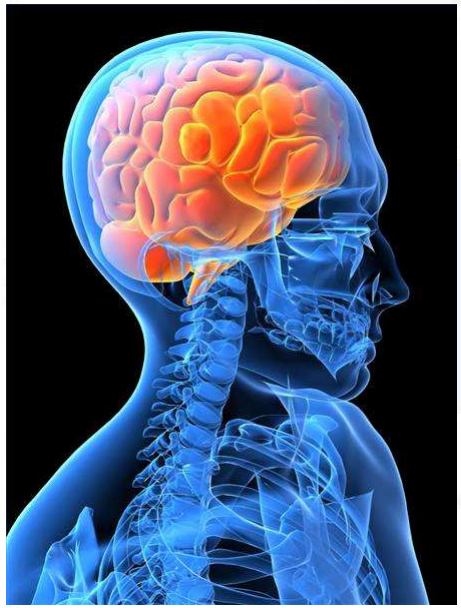

Telencephalon – part 1 (“endbrain”)

1. Telencephalon (cerebrum) – general overview
2. Embryonic and postnatal development
3. Cerebral hemispheres:
   - ✓ surface anatomy – major sulci, gyri and lobes
   - ✓ cerebral cortex – microscopic structure, cyto- and myeloarchitecture
   - ✓ cerebral white matter – association, commissural and projection fibers
     - ➢ cortical commissures, corpus callosum and internal capsule
4. Basal ganglia – structural and functional considerations
5. Lateral ventricle

Cerebrum – general overview

- weight ~ 1100 g
- 80% of the total brain mass
- cerebral hemispheres:
  - ✓ pallium
    - ➢ superficial grey matter (cerebral cortex)
    - ➢ deep grey matter (basal ganglia)
    - ➢ white matter
    - ➢ ventricular cavity (lateral ventricle)
  - ✓ longitudinal fissure of the cerebrum:
    - ➢ *falx cerebri*
    - ➢ *corpus callosum*

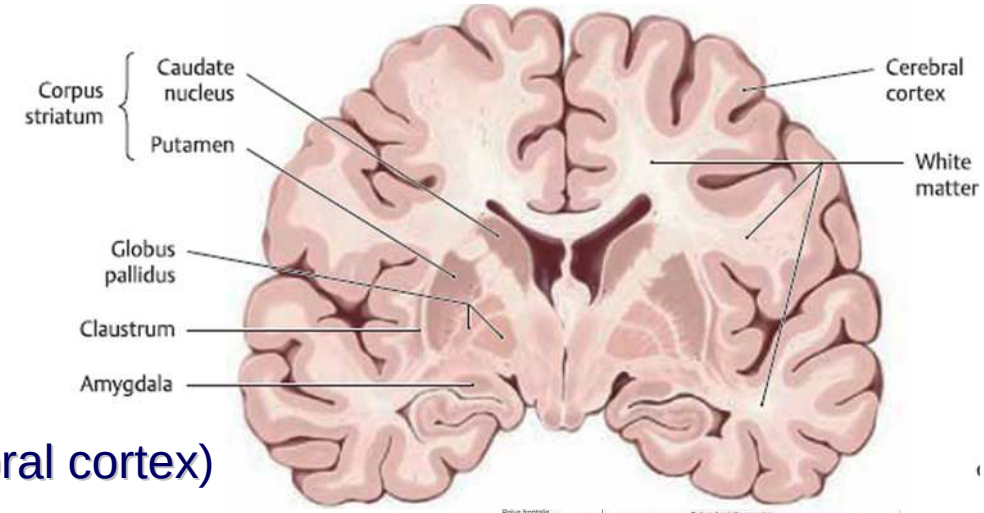

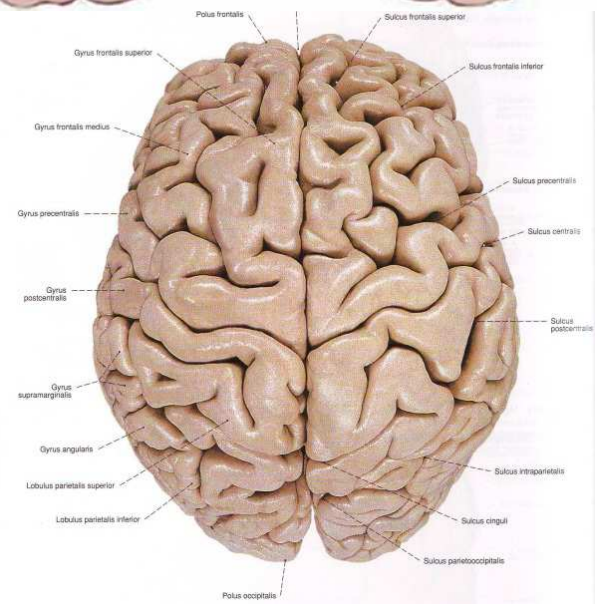

Telencephalon – development

- Embryonic origin – rostral part of the ***prosencephalon***
  - ✓ cortex formation
  - ✓ fissuration/sulcation

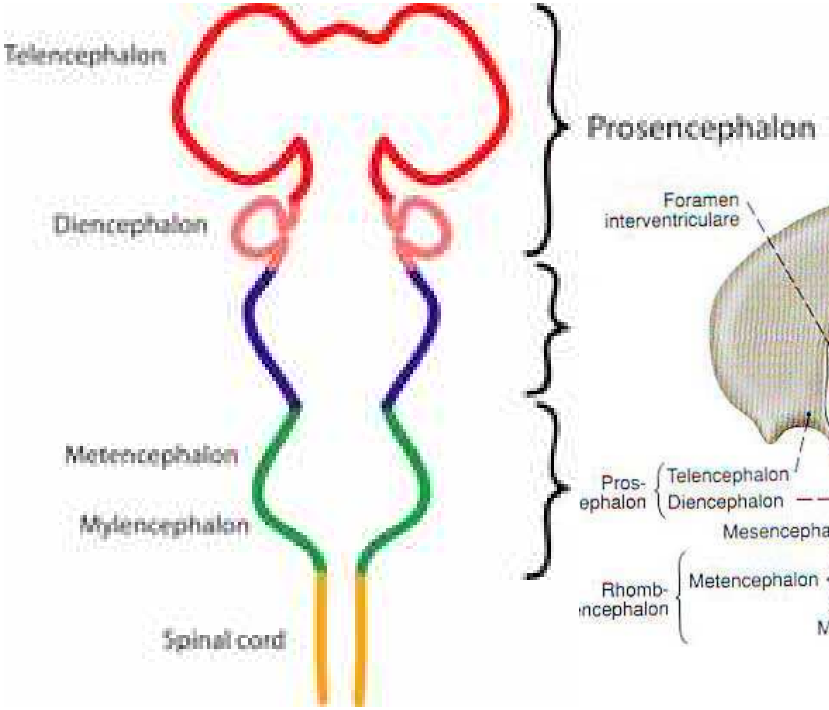

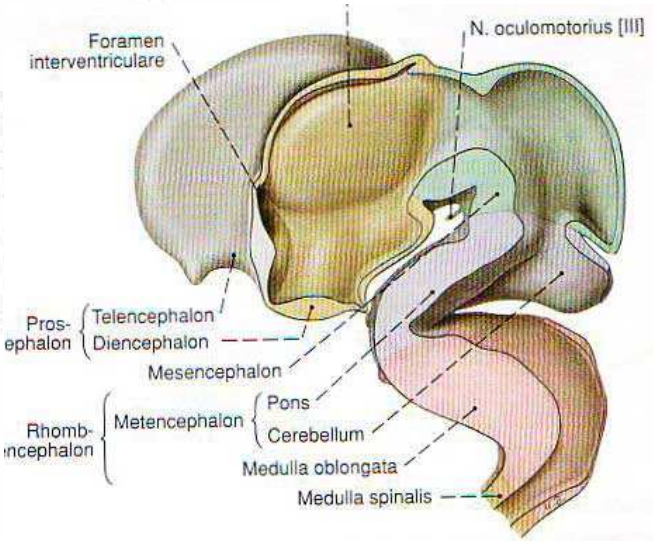

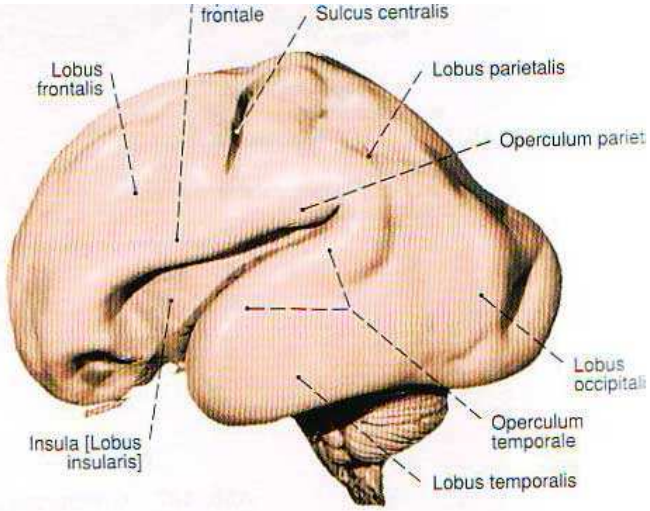

- at birth ~ 340 g = 1/10 of the total body weight
- up to 9th postnatal month – weight duplication
- mid-3 year ~ 1000 g
- about 20 years of age – definitive size and weight

Cerebral hemispheres

- **three surfaces:**
  - ✓ superolateral (convex)
  - ✓ medial (flat and vertical)
  - ✓ inferior (irregular):
    - ➢ orbital part
    - ➢ tentorial part

- **six lobes:**
  - ✓ frontal lobe
  - ✓ parietal lobe
  - ✓ occipital lobe
  - ✓ temporal lobe
  - ✓ insular lobe
  - ✓ limbic lobe

- **main sulci:**
  - ✓ central sulcus (of *Rolando*)
  - ✓ lateral sulcus (of *Sylvius*)
  - ✓ parietooccipital sulcus
  - ✓ cingulate sulcus ⇨ collateral sulcus

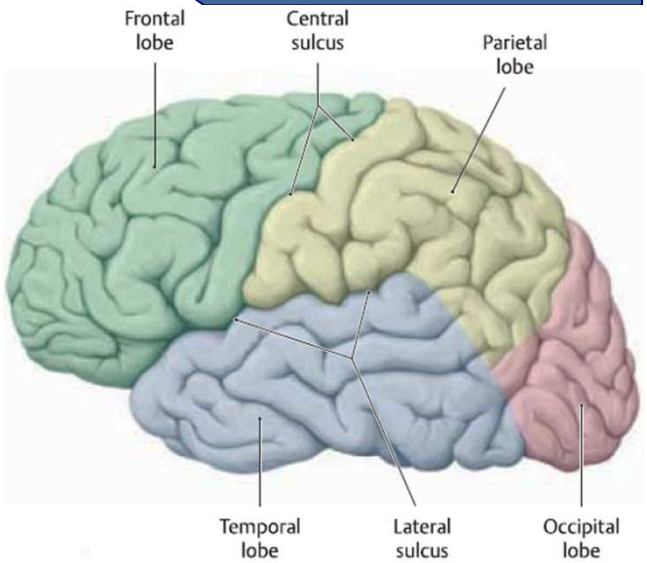

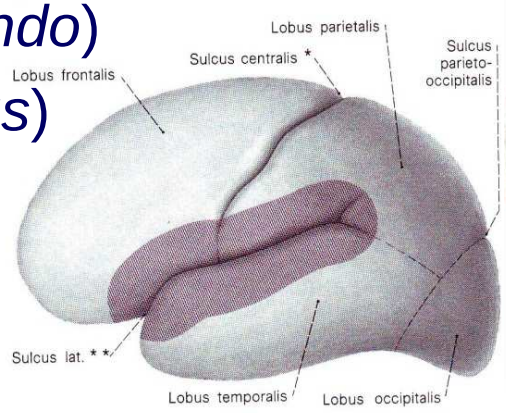

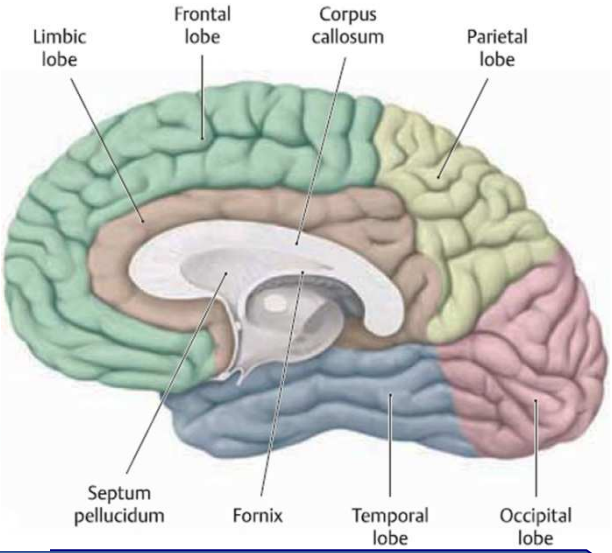

NB: *sulcus* (Latin: "furrow", pl. *sulci*)

Superolateral surface

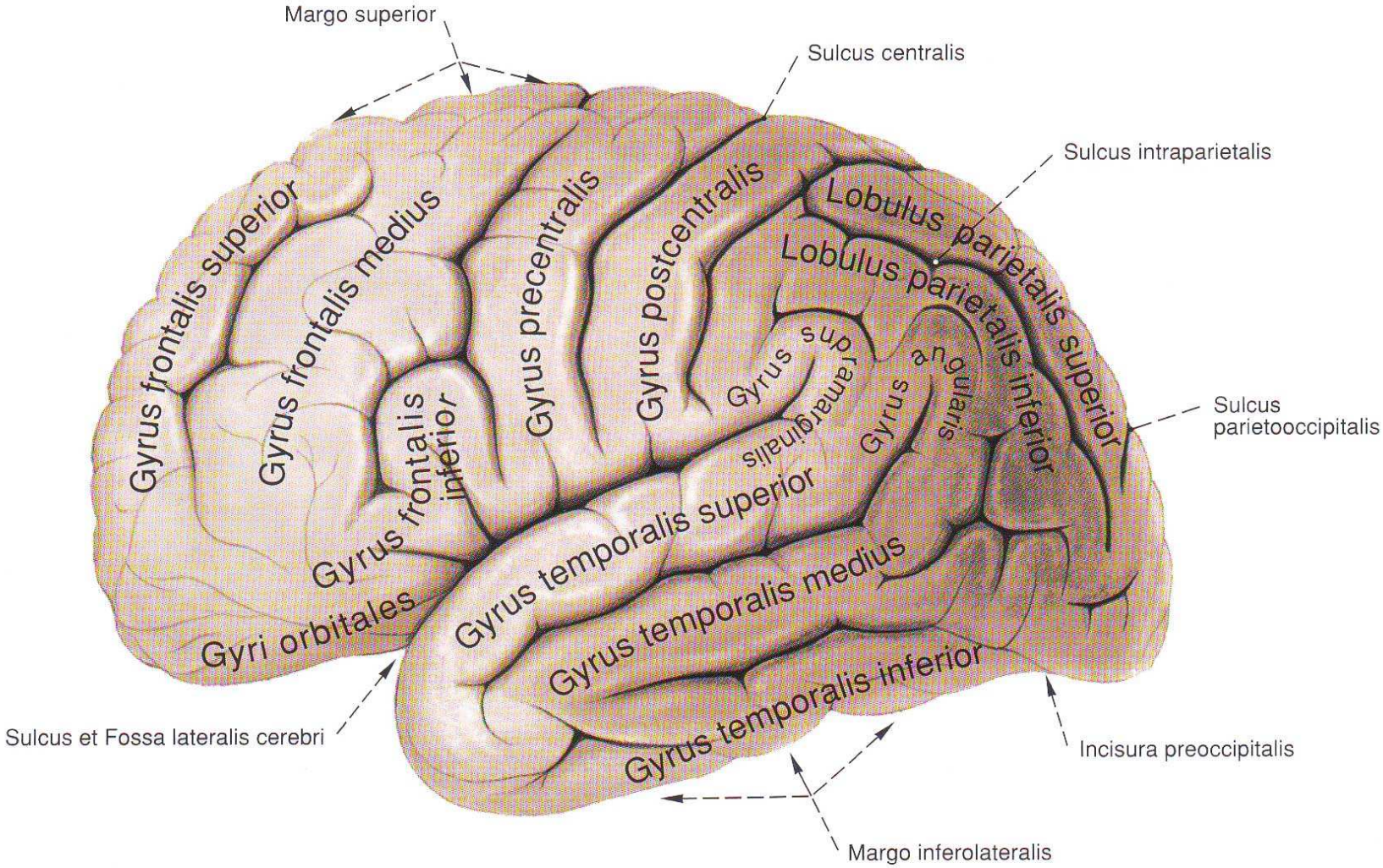

Superolateral surface

✓ *insular lobe* (insula, island of *Reil*)

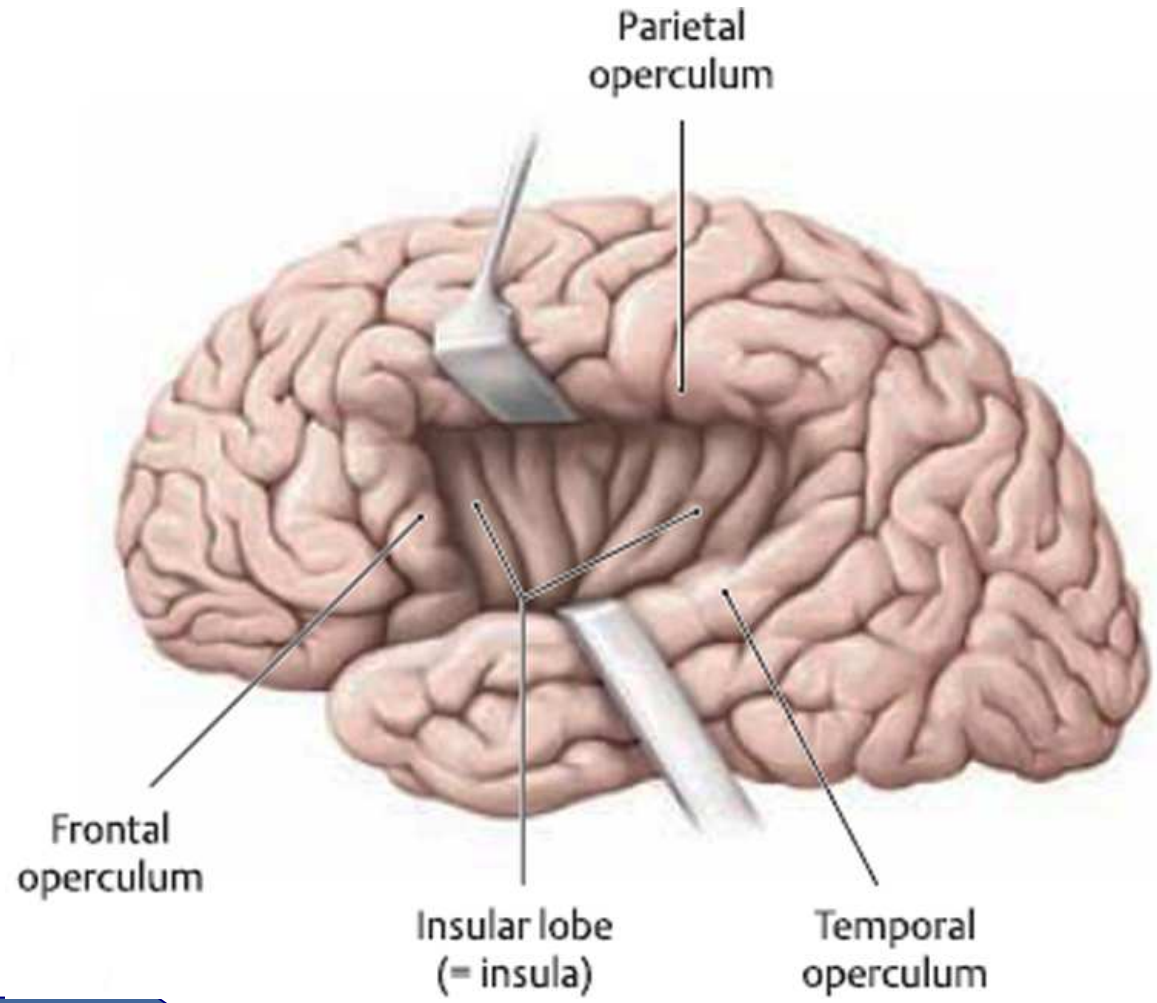

Medial surface

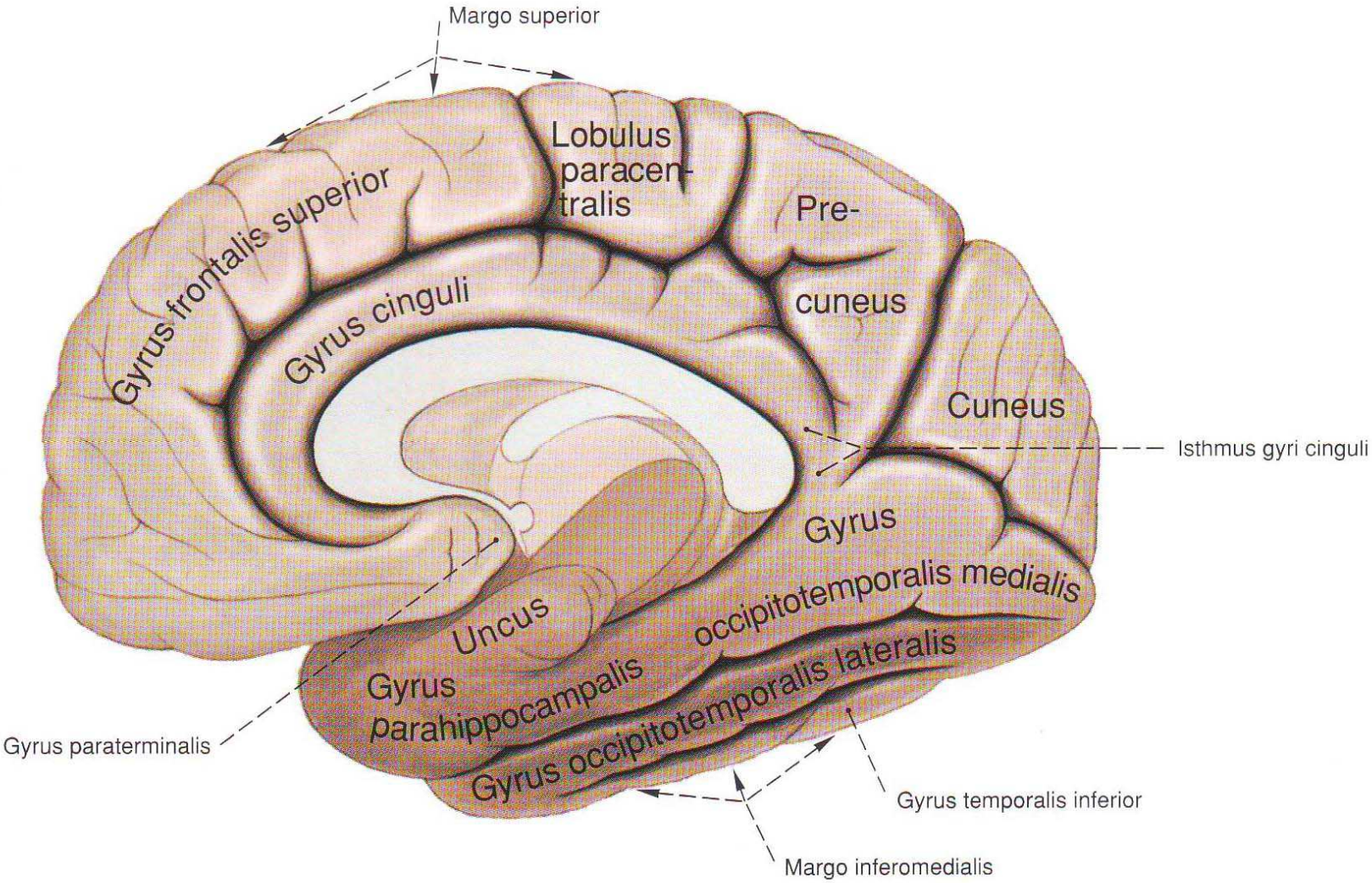

Inferior surface

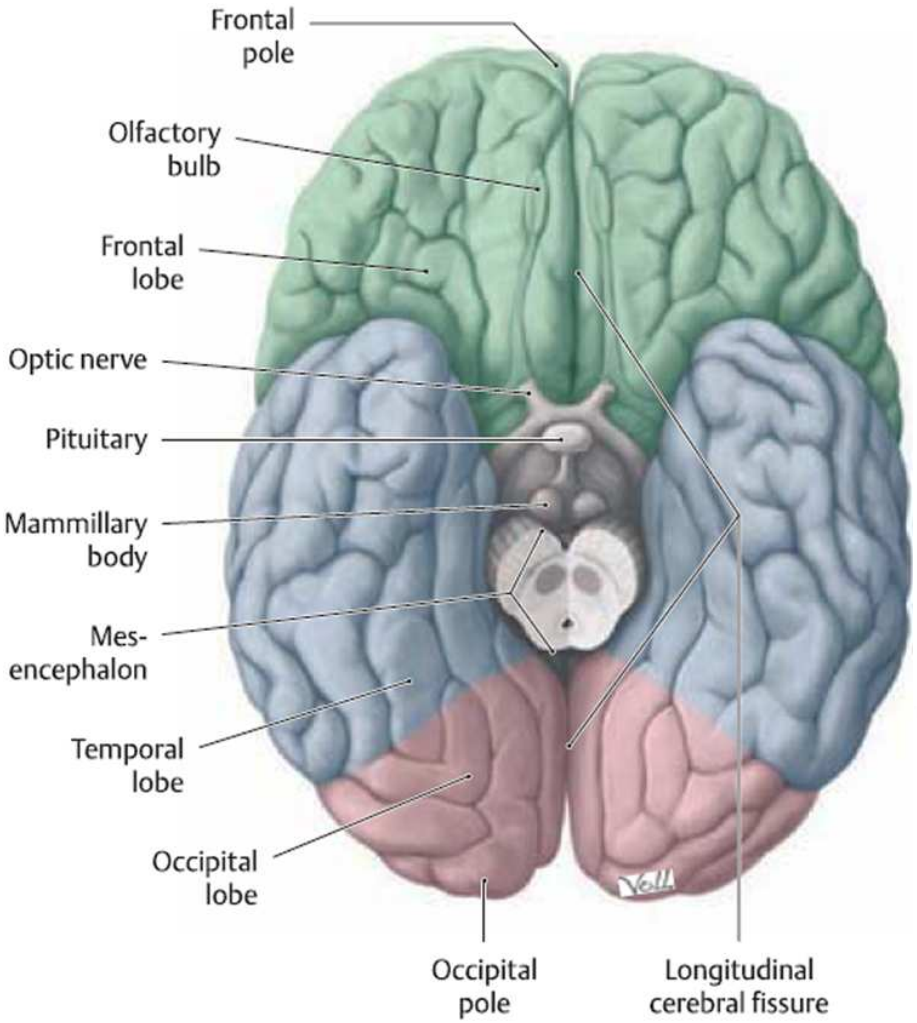

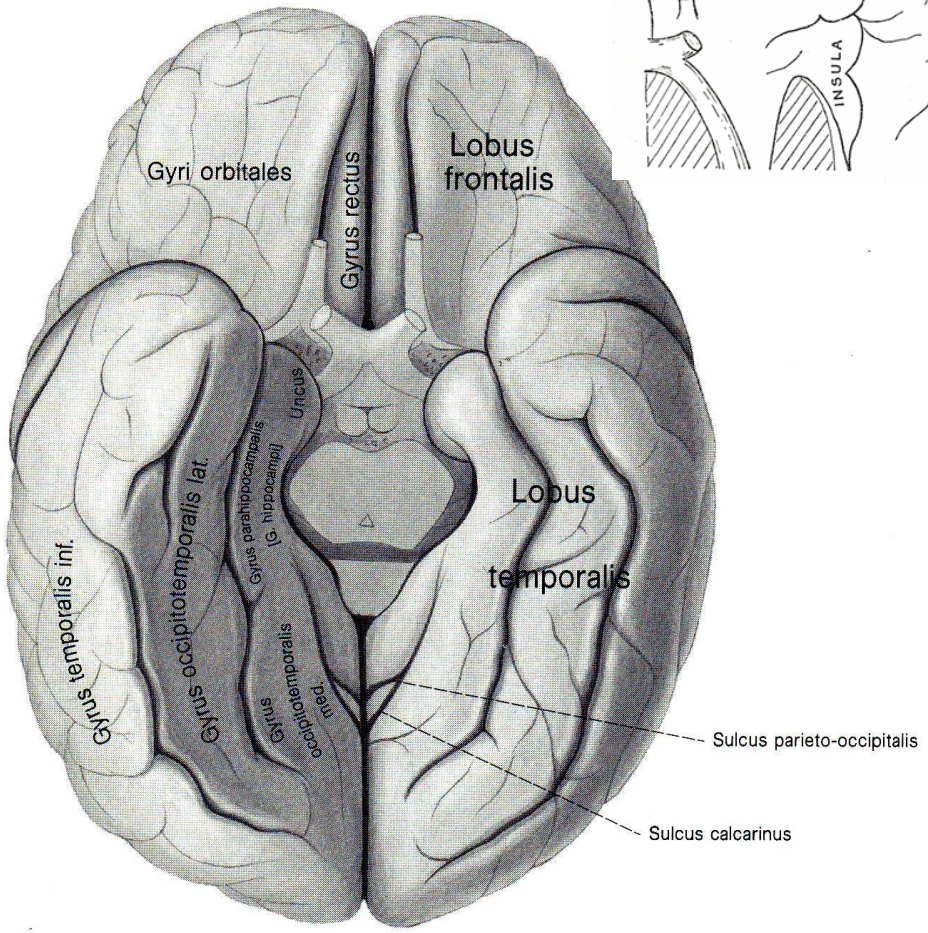

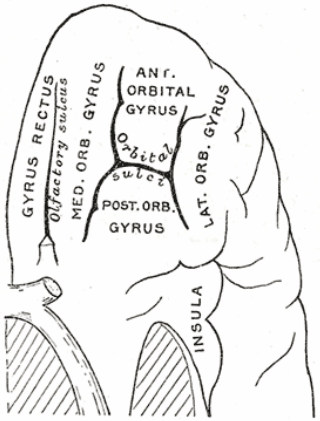

Cerebral cortex

- surface area: approx. 2200-2850 cm^2
- thickness:
  - 1.5 mm – frontal and temporal poles
  - 5 mm – in the precentral gyrus
- total number of cortical neurons:
  - 2.6-20 billion

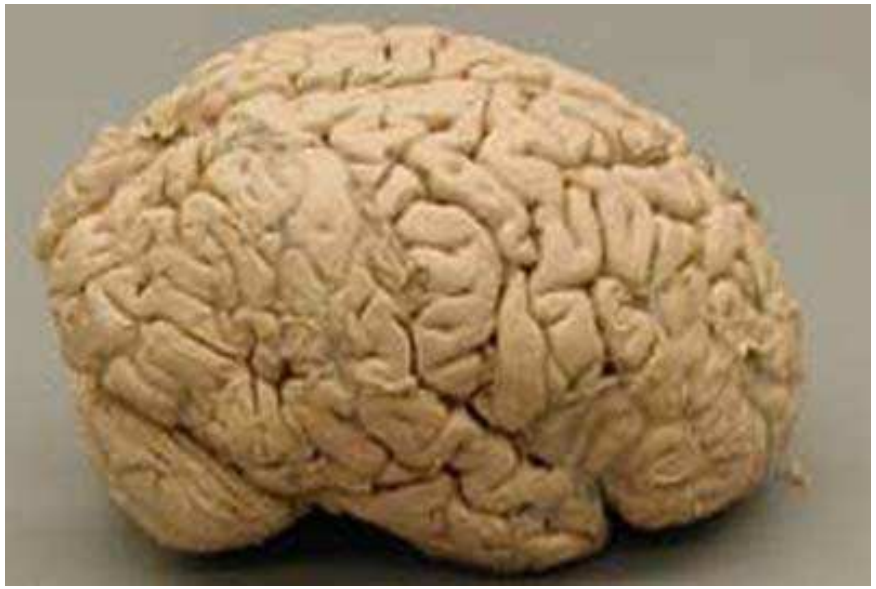

- 0.6×10^9 synapses per mm^3
- 60000 synapses over one pyramidal neuron
- one pyramidal nerve cell – 600 neurons

NB: The human brain contains roughly 90 billion neurons, which transmit information across roughly 150 trillion synapses!

Cortical cell types

- pyramidal cells – 66% of the total neocortical cell population (glutamate- and aspartatergic)
  - ✓ small-sized (10-15 µm)
  - ✓ medium-sized (20-40 µm)
  - ✓ large-sized (50-80 µm)
  - ✓ giant pyramidal cells of *Betz* (80-120 µm) – in the precentral gyrus (motor cortex)
- stellate (granule) cells – 33% of the total neocortical population (*Golgi* type II cells)
  - ✓ small in size (8-14 µm) – interneurons (GABA, VIP, SP, CCK, ENK)
    - ➢ horizontal cells of *Cajal* – small and fusiform; in the most superficial cortical layer
    - ➢ fusiform cells – "modified pyramidal cells"; spindle-shaped, in the deepest cortical layer
    - ➢ cells of *Martinotti* – small and multipolar; in practically all cortical layers
    - ➢ basket cells – horizontally extended
    - ➢ neurogliaform stellate cells – small in size
- pleomorphic cells – modified pyramidal cells; – large-sized and varying in shape, in the deepest layer

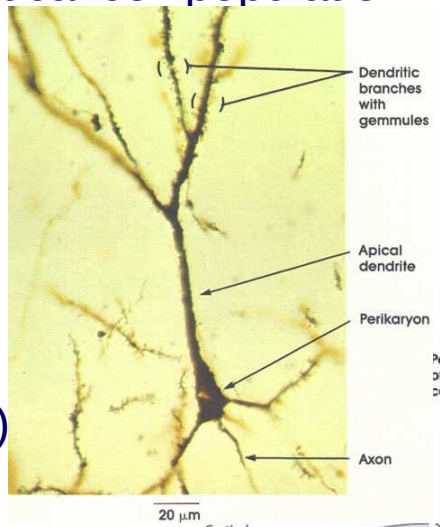

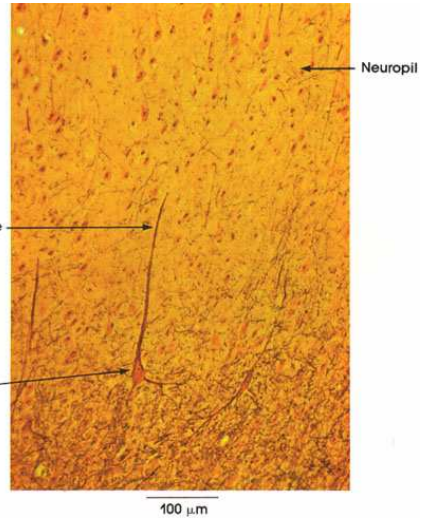

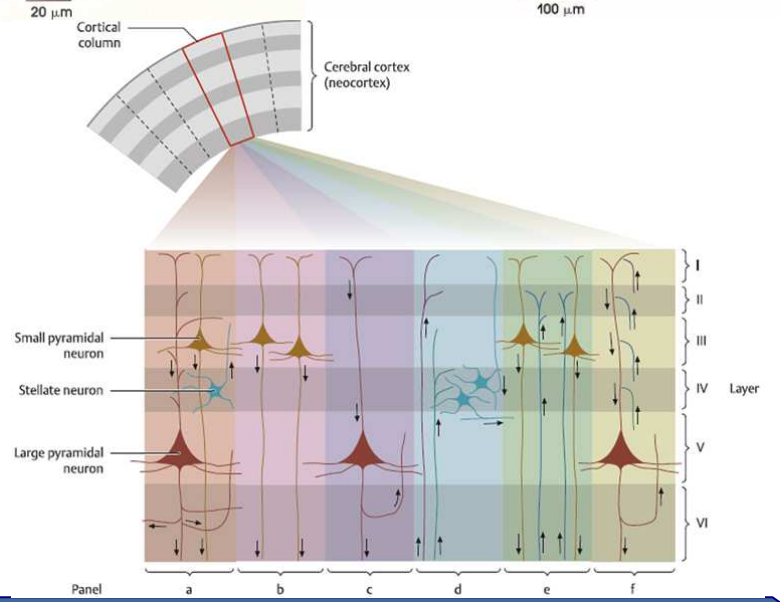

Cytoarchitectonic mapping

- *neocortex* (*Latin for "new bark" or "new rind"*) – 6-layered;
  neopallium (*"new mantel"*) – 90% of hemispheric surface
  isocortex *(Greek isos = "equal rind");*
  phylogenetically newer part of the cortex
- *allocortex, archipallium* – the older, original part of the cerebral cortex;
  (Gr. allos = "different, other, another");
  fewer than six layers – 3- or 4-layered:
  - ✓ *paleocortex, paleopallium* – 1% of the cerebral cortex
    (Gr. palaios = "ancient, old"); 4-layered,
    ⇨ olfactory cortex *(rhinencephalon)*
  - ✓ *archaeocortex, archipallium* – 3-4% of the cortex
    (Gr. arche = "beginning"); 3-layered,
    ⇨ hippocampal cortex
- *mesocortex* – intermediate in form between the allocortex and the isocortex;
  5-6-layered, ⇨ cingulate gyrus

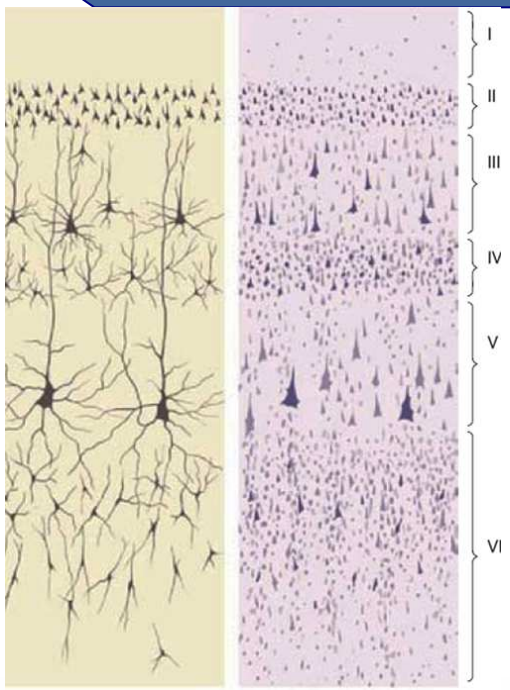

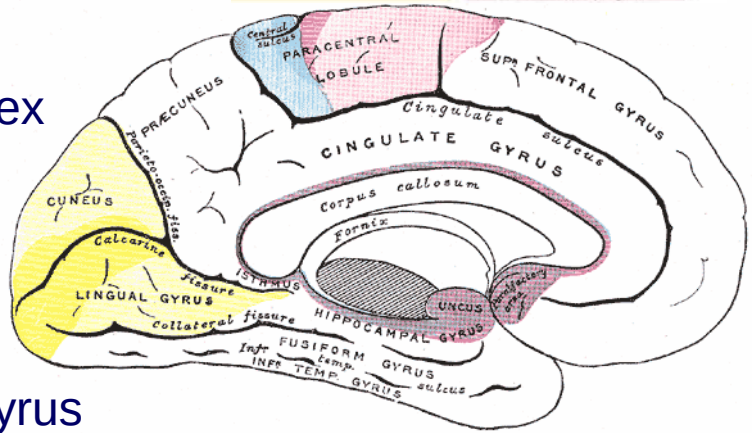

Laminar pattern in the cerebral cortex

Cortical layers *(Brodmann):*

I. Molecular layer (plexiform lamina)
II. External granular lamina
III. External pyramidal lamina
IV. Internal granular lamina
V. Internal pyramidal (ganglionic) lamina
VI. Multiform (fusiform) lamina

- *Meynert* – 5 layers (laminae)
- *B. Lewis* – 6 layers

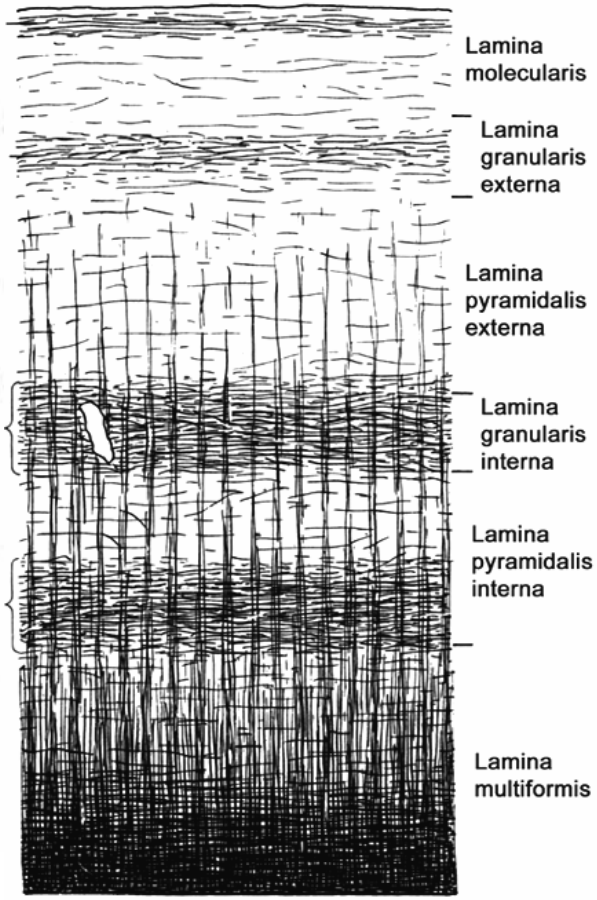

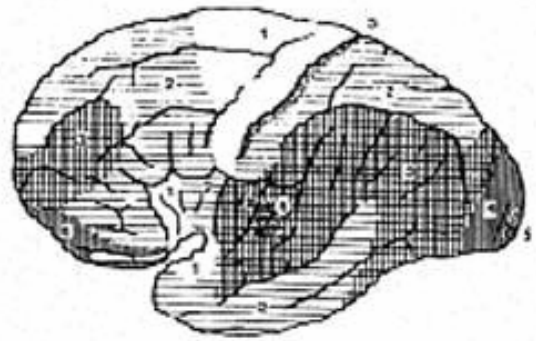



Variants of neocortical structure

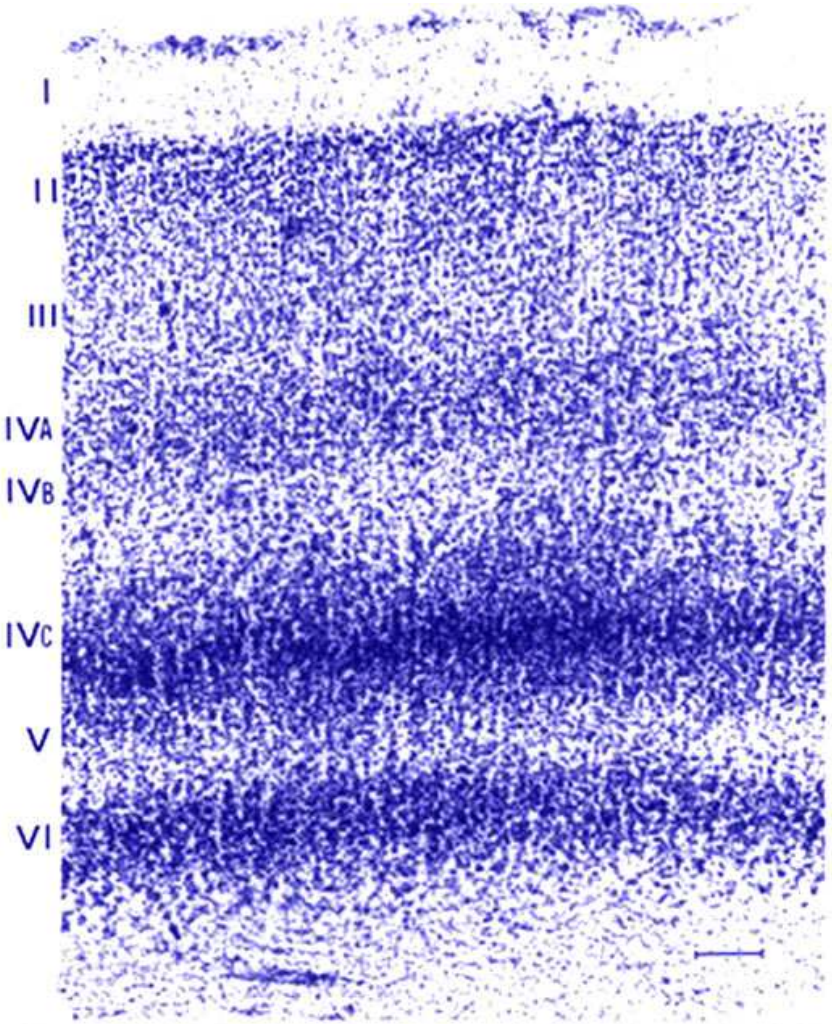

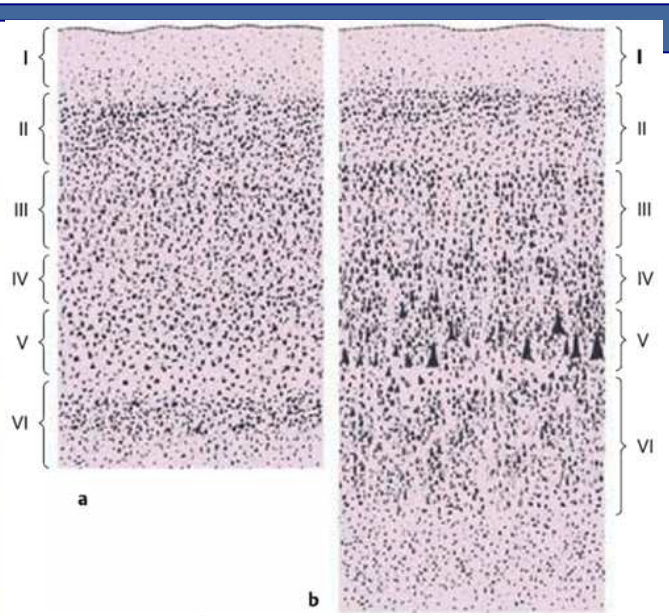

5 major types of cerebral cortex:

- heterotypical cortex *(Brodmann):*
  - ✓ agranular type – III, V, VI (motor cortex)
  - ✓ granular type (koniocortex) – II, IV layers (sensory cortex)
- homotypical cortex:
  - ✓ frontal type cortex – premotor cortex
  - ✓ parietal type – postcentral cortex
  - ✓ polar type – visuopsychic cortex

Myeloarchitecture: cortical fiber structure

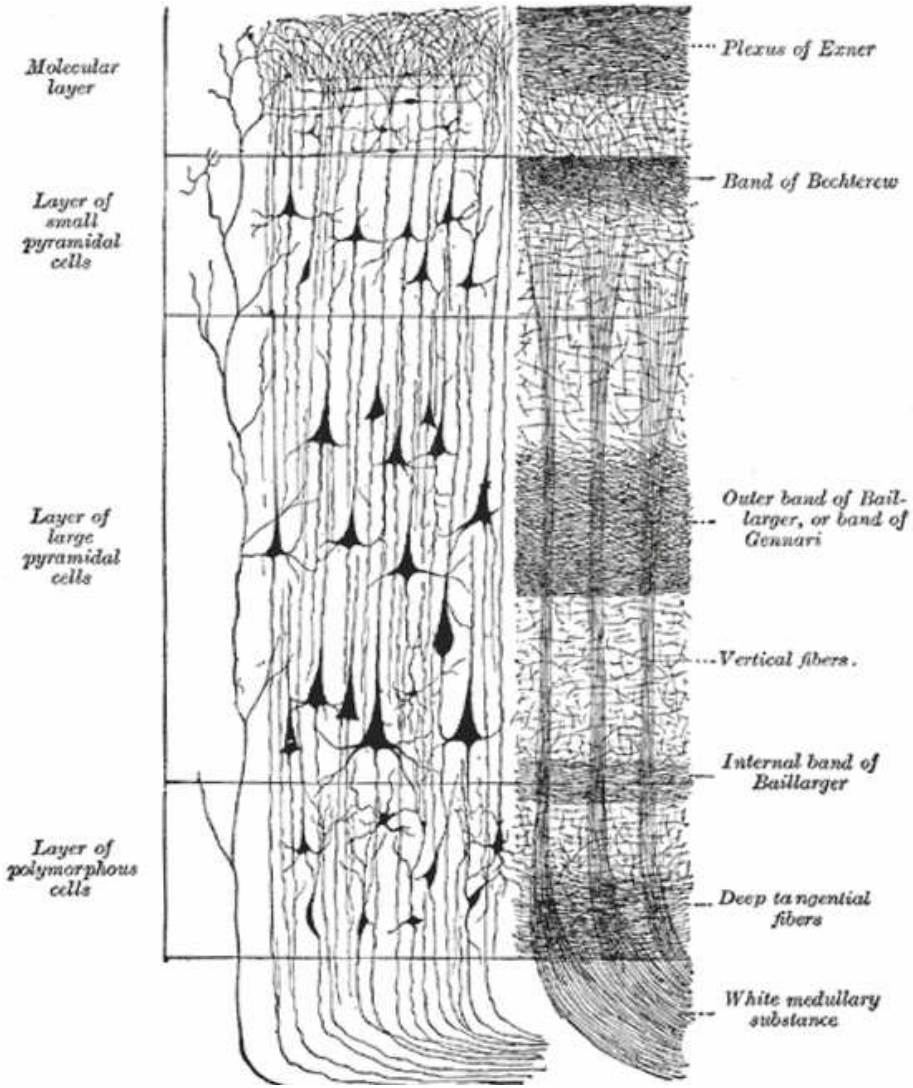

- *Flechsig* – 35 myelogenic areas
- C. and O. *Vogt* – 400 areas
- *stria laminae molecularis (plexiformis),* (plexus of *Exner*)
- *stria laminae granularis externae* (band of *Bechterew*)
- *stria laminae granularis internae* (external band of *Baillarger,* or band of *Gennari*)
  - *in sulcus calcarinus* *(area striata* – band of *Vicq d'Azyr)*
- *stria laminae pyramidalis internae (ganglionaris),* (internal band of *Baillarger*)

Cerebrum – white matter

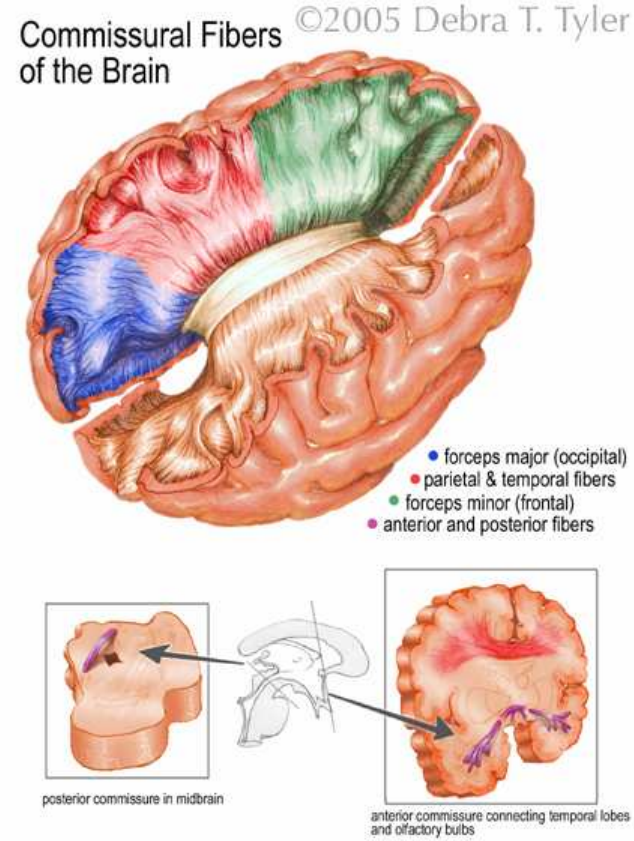

- Three vast fiber systems:
  - ✓ association fibers – *fibrae associationes telencephali*
  - ✓ commissural fibers – *fibrae commissurales telencephali*
  - ✓ projection fibers – *fibrae projectiones telencephali*

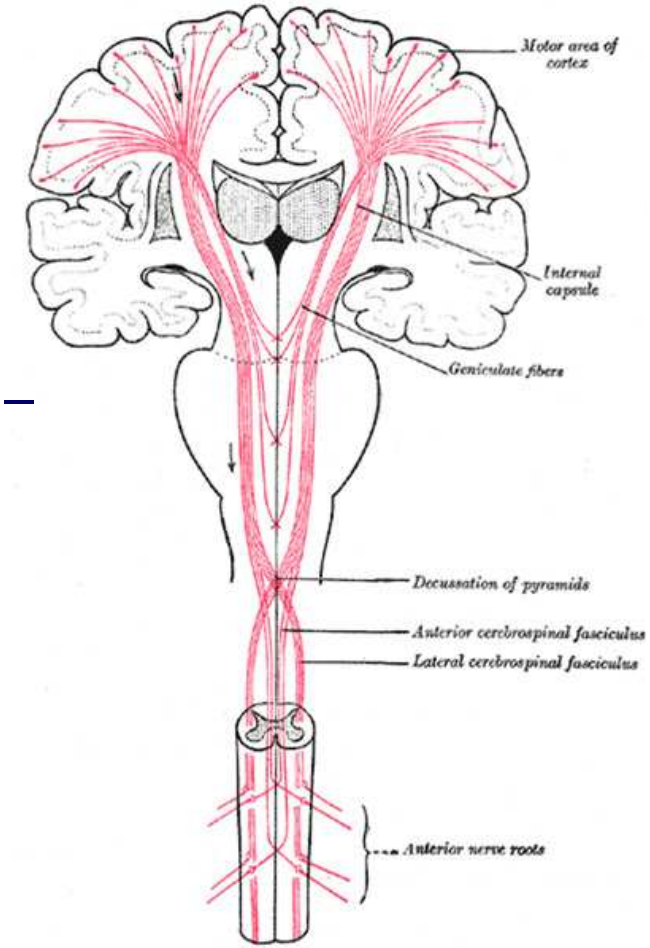

Association fibers

- short association fibers:
  - ✓ *fibrae arcuatae cerebri* (U fibers)
- long association fibers:
  - ✓ *cingulum*
  - ✓ *superior longitudinal fasciculus*
  - ✓ *inferior longitudinal fasciculus*
  - ✓ *uncinate fasciculus* ⇨ *inferior frontooccipital fasciculus*
  - ✓ *arcuate fasciculus*
  - ✓ *vertical occipital fasciculus*

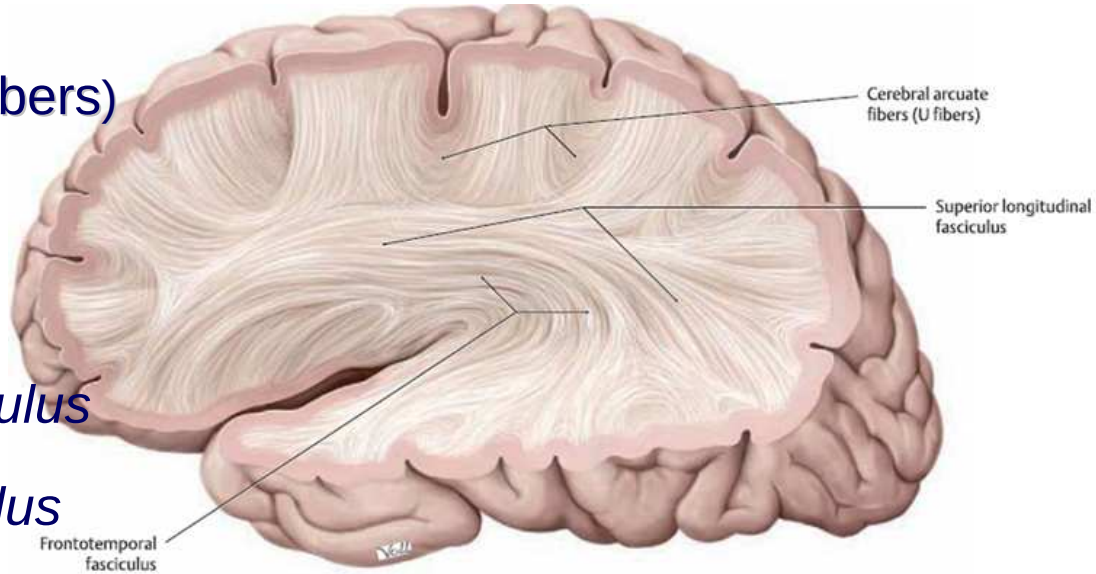

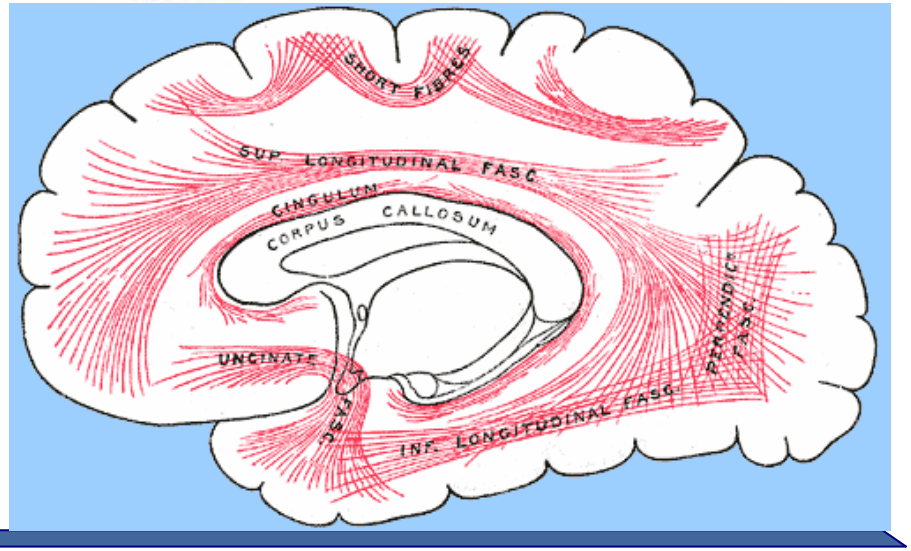

Commissural fibers

- anterior (rostral) commissure
- commissure of the fornix (hippocampal commissure)
- commissura magna (corpus callosum)

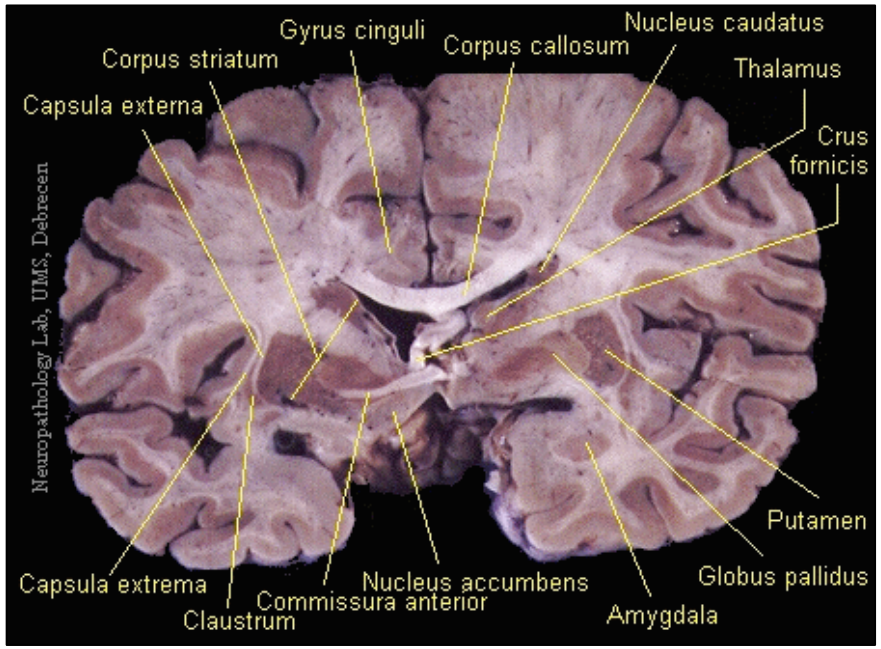

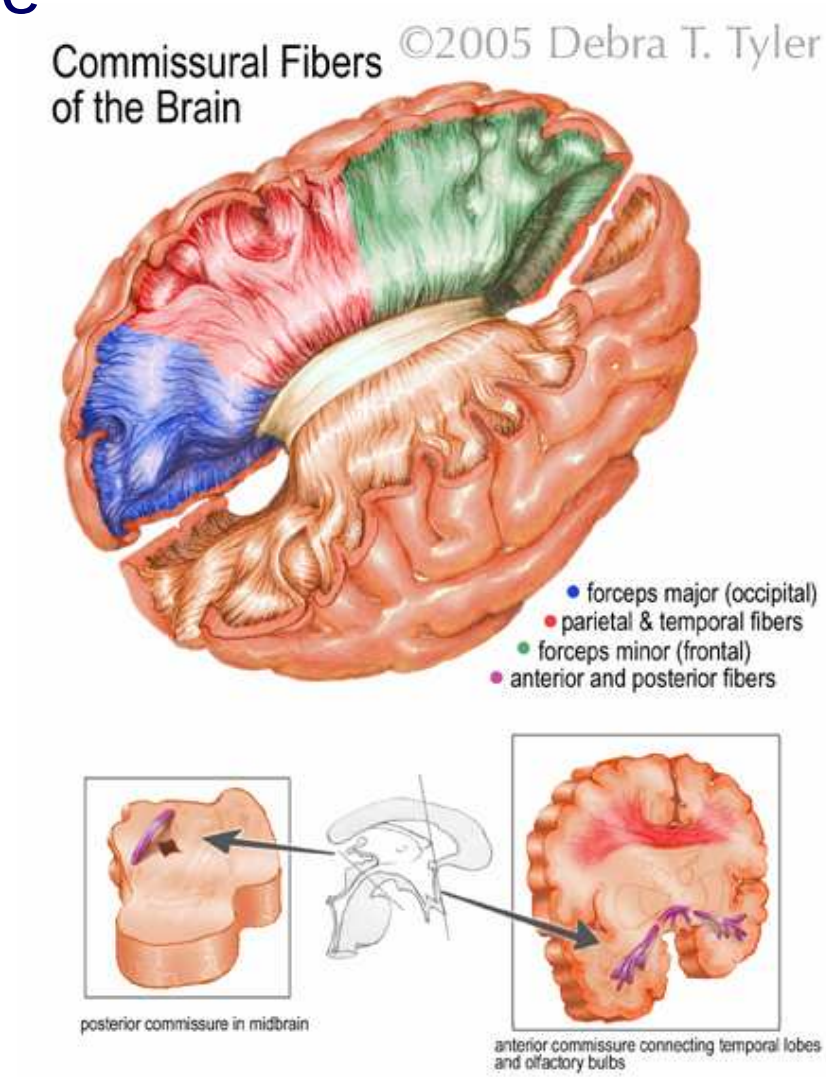

Corpus callosum

- broad, thick plate of myelinated fibers ~ 10 cm in length
  - ✓ *rostrum corporis callosi*
  - ✓ *genu corporis callosi*
  - ✓ *truncus corporis callosi*
  - ✓ *splenium corporis callosi*
  - ✓ *forceps minor* (frontal)
  - ✓ *forceps major* (occipital)
  - ✓ *indusium griseum* – limbic system
    - ➢ *stria longitudinalis medialis (Lancisii)*
    - ➢ *stria longitudinalis lateralis*

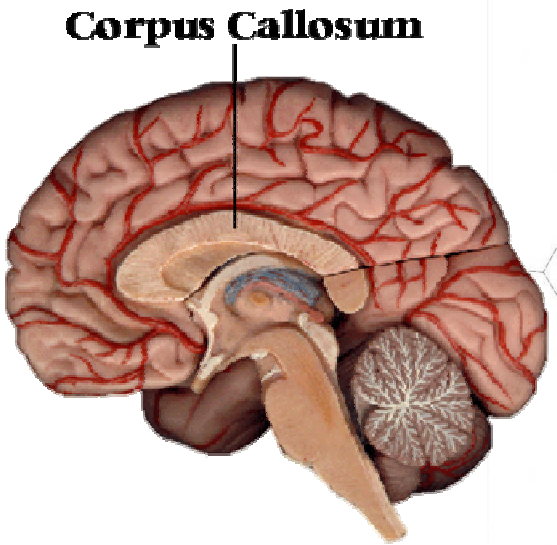

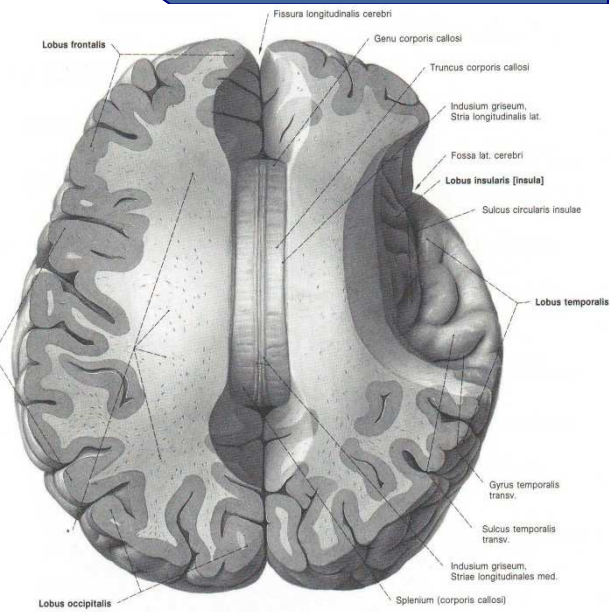

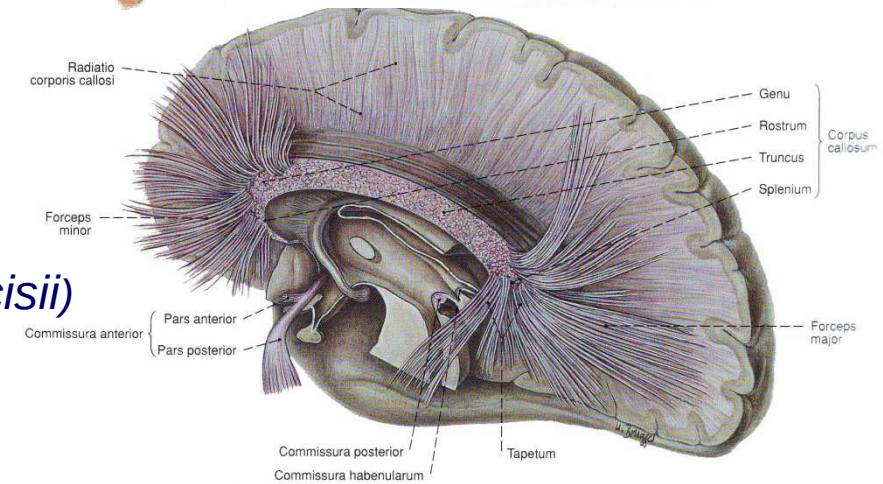

Projection fibers

- internal capsule:
  - ✓ anterior limb – 1.5 cm
    - ➢ *radiatio thalami anterior*
    - ➢ *tractus frontopontinus* (of *Arnold*)
    - ➢ *fibrae corticostriatae*
  - ✓ *genu capsulae internae*
    - ➢ *fibrae corticonucleares*
  - ✓ posterior limb:
    - ➢ thalamolentiform part
      - *fibrae corticospinales*
      - *fibrae corticorubrales*
      - *fibrae corticoreticulares*
    - ➢ retrolentiform part
      - *radiatio thalami posterior*
      - *tractus parietooccipitopontinus*
    - ➢ sublentiform part
      - *radiatio optica* (tract of *Gratiolet*)
      - *radiatio acustica*
      - *fibrae corticotectales*
      - *fibrae temporopontinae* (tract of *Türk*)

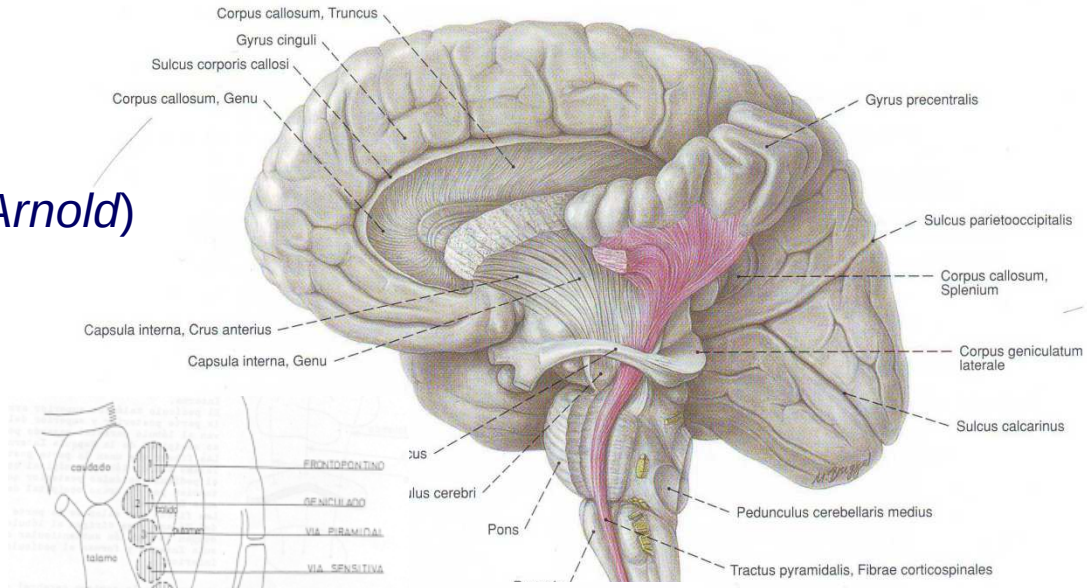

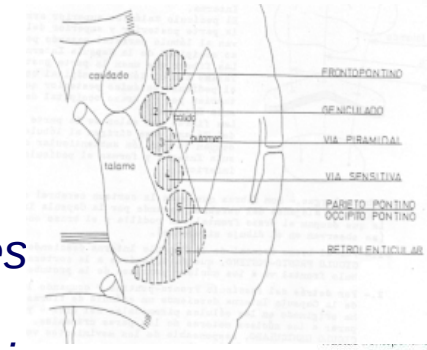

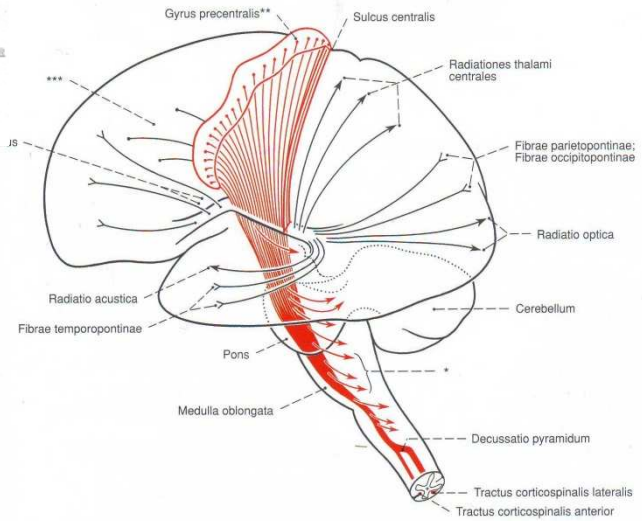

Basal nuclei (“Basal ganglia”)

- Classically:
  - ✓ *nucleus caudatus*
  - ✓ *nucleus lentiformis*
  - ✓ *claustrum*
  - ✓ *corpus amygdaloideum* – limbic system

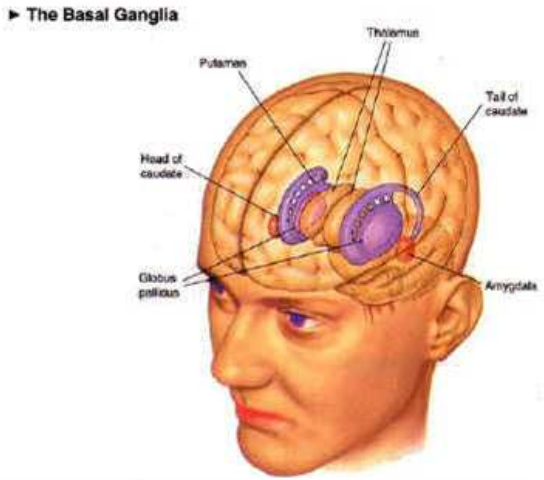

- The International Basal Ganglia Society:
  - ✓ *nucleus caudatus*
  - ✓ *nucleus lentiformis*
  - ✓ *nucleus subthalamicus*
  - ✓ *substantia nigra*

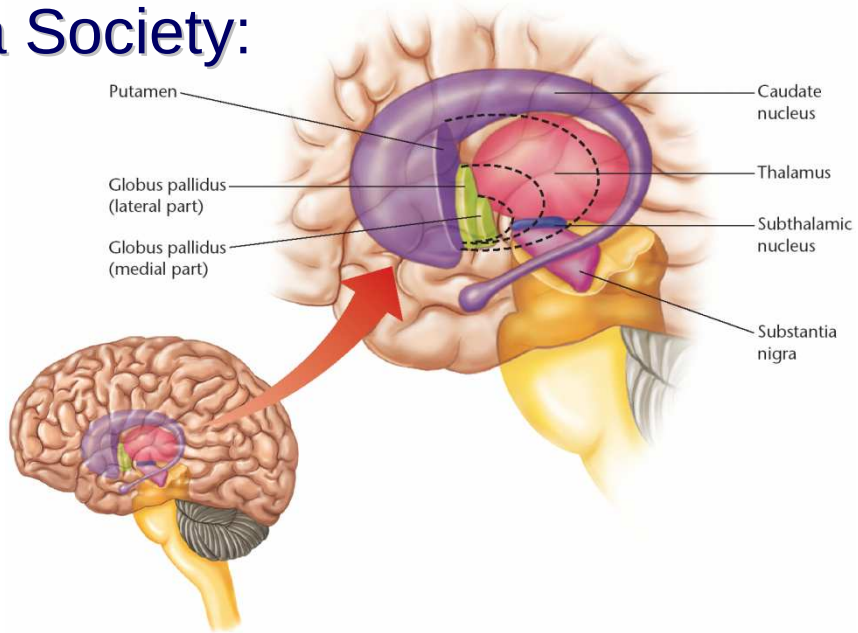

Claustrum

- Lat. *claudere* – barrier
- ✓ a thin (1-2 mm) lamina of grey matter
- ✓ *capsula externa*
- ✓ *capsula extrema*
- ✓ part of lentiform nucleus?
- ✓ part of insular cortex?
- ✓ polysensory integrator

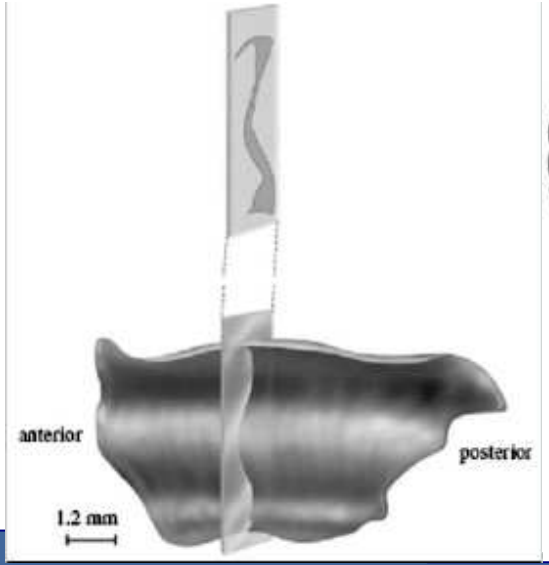

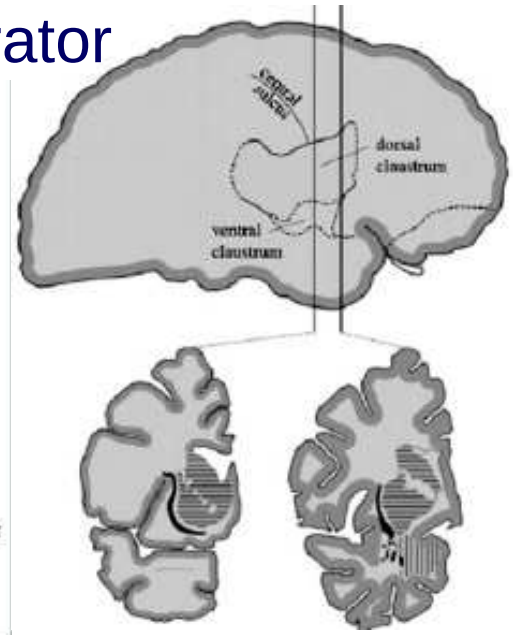

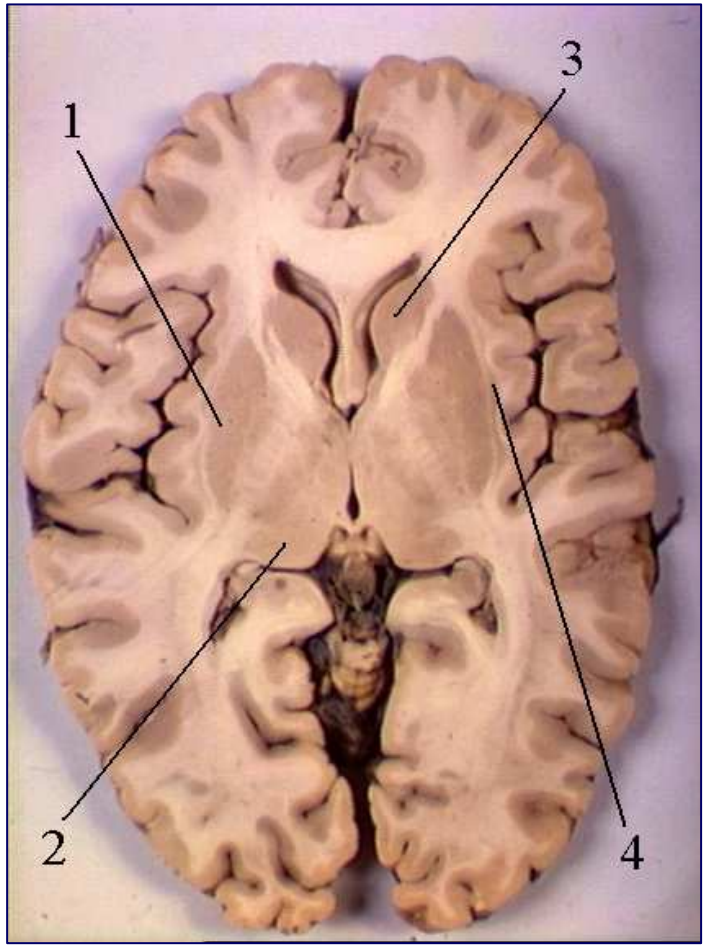

Caudate nucleus

- arcuate mass of grey matter
- length ~ 7 cm
- parts:
  - ✓ head *(caput nuclei caudati)*
  - ✓ body *(corpus nuclei caudati)*
  - ✓ tail *(cauda nuclei caudati)*

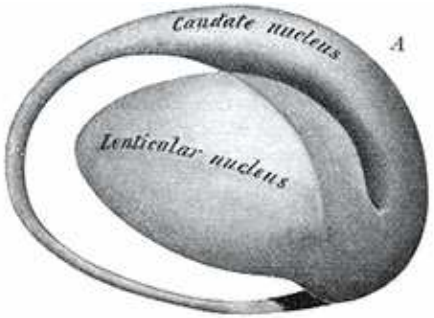

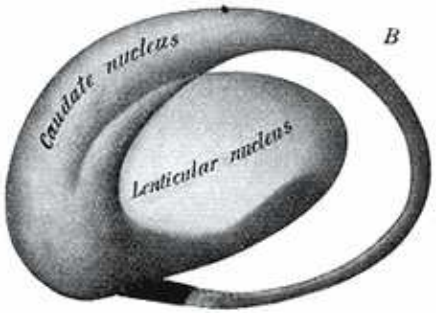

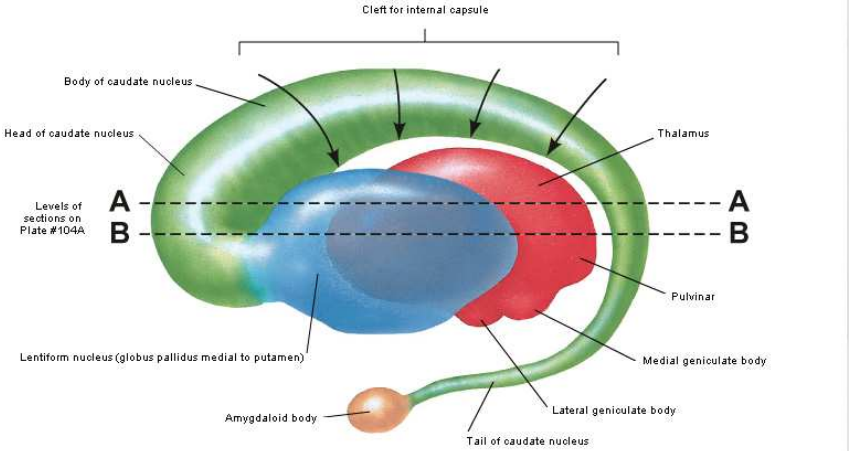

Interrelationship of thalamus, lentiform nucleus, caudate nucleus and amygdaloid body

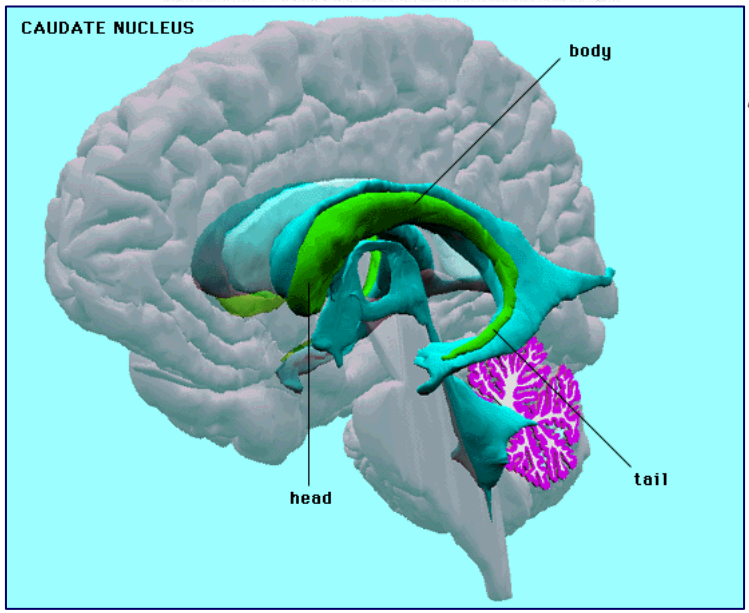

Lentiform nucleus

- *putamen + nucleus caudatus = striatum (neostriatum)*
- *globus pallidus = pallidum (palleostriatum):*
  - ✓ *globus pallidus lateralis (pallidum externum)*
  - ✓ *globus pallidus medialis (pallidum internum)*

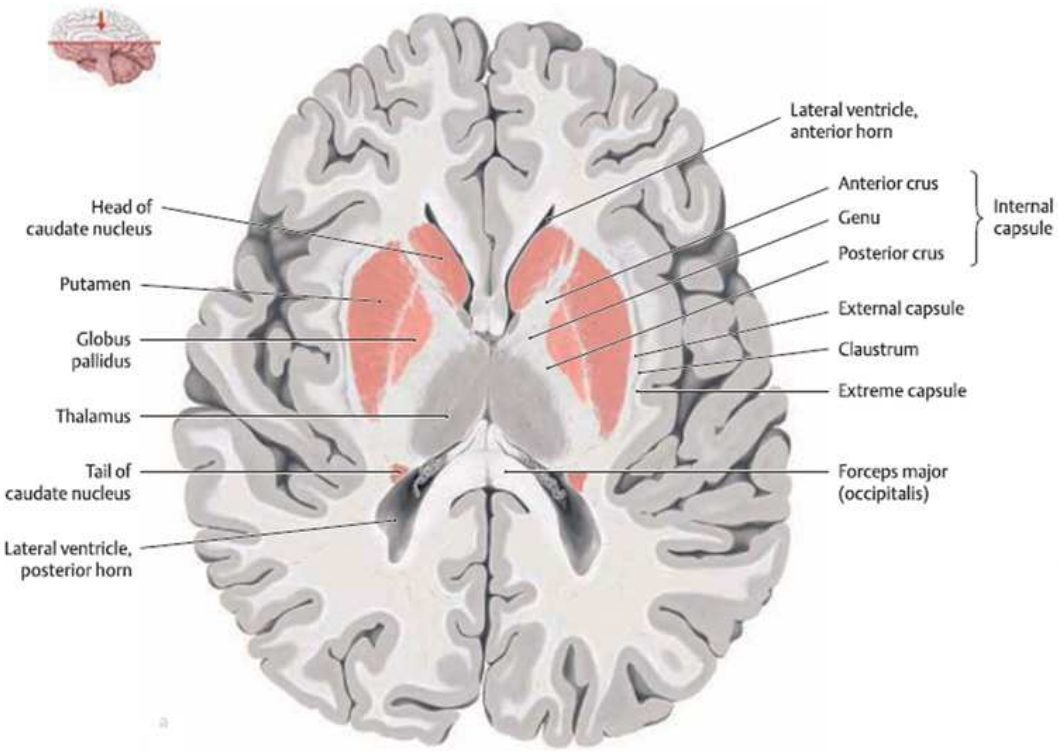

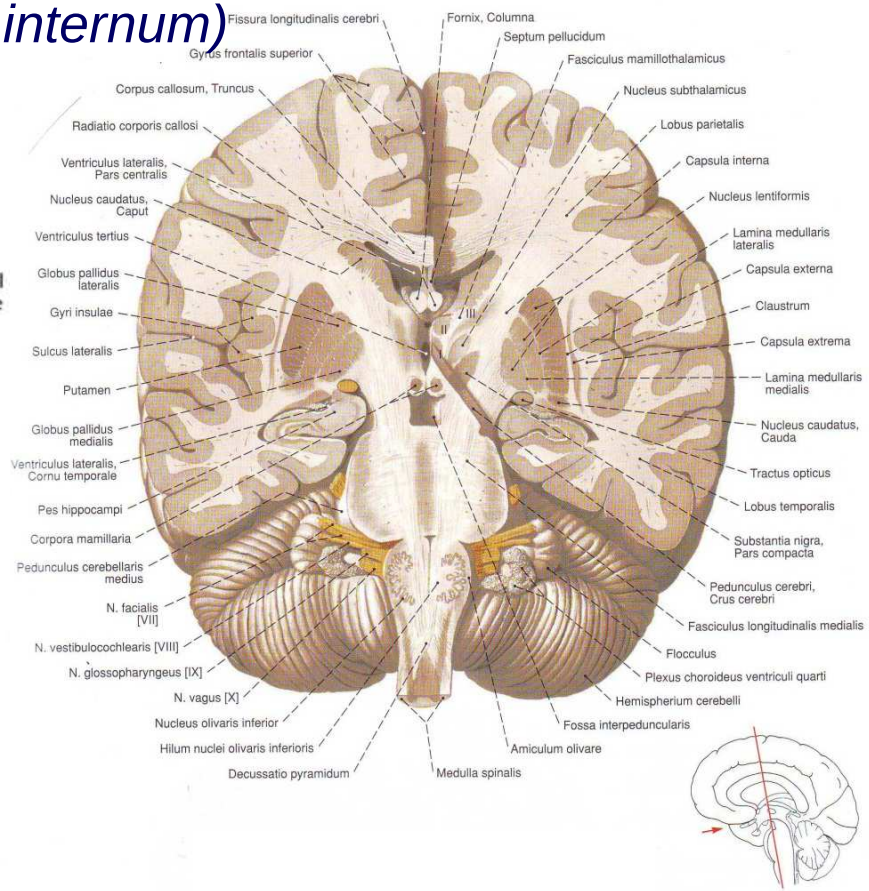

Striopallidal system

✓ *striatum + pallidum*

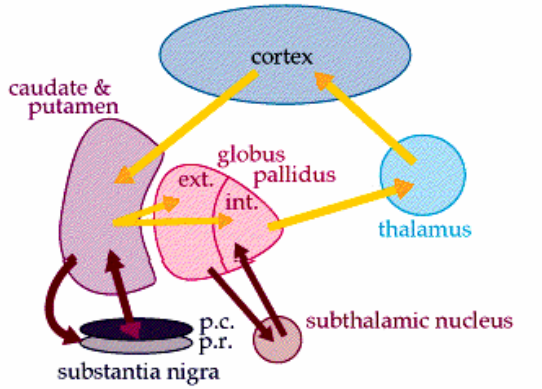

- functions:
  - ✓ role in the planning and modulation of movements
  - ✓ involved in a variety of cognitive processes involving executive function
- pathology:
  - ✓ dyskinesia (tremor, athetosis, chorea, ballismus)
  - ✓ muscle rigidity
  - ✓ *paralysis agitans* (Parkinson's disease)
  - ✓ Huntington's chorea



Lateral ventricle

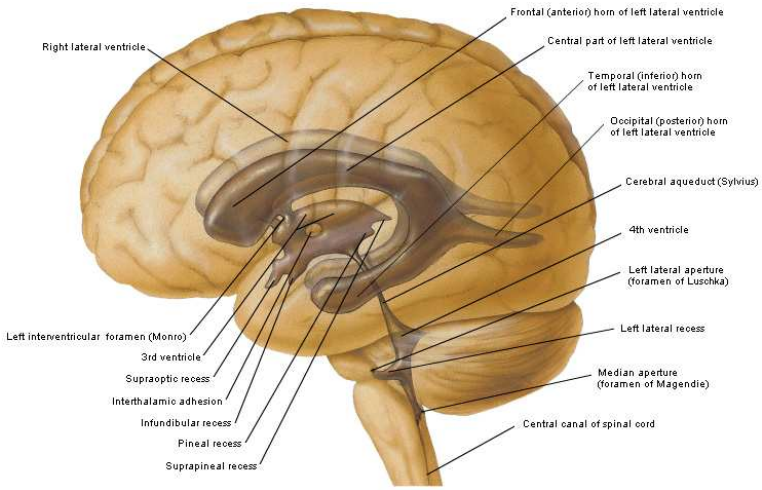

- ✓ Left lateral ventricle – first ventricle?
- ✓ Right lateral ventricle – second ventricle?

NB: Since they are symmetric, a numbering system was not used for the lateral ventricles!

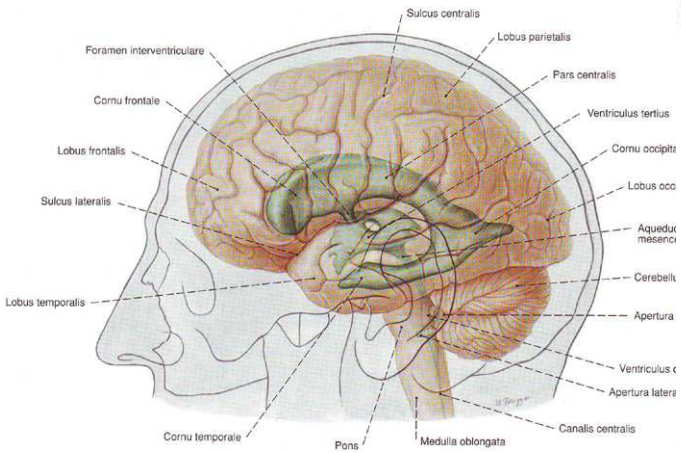

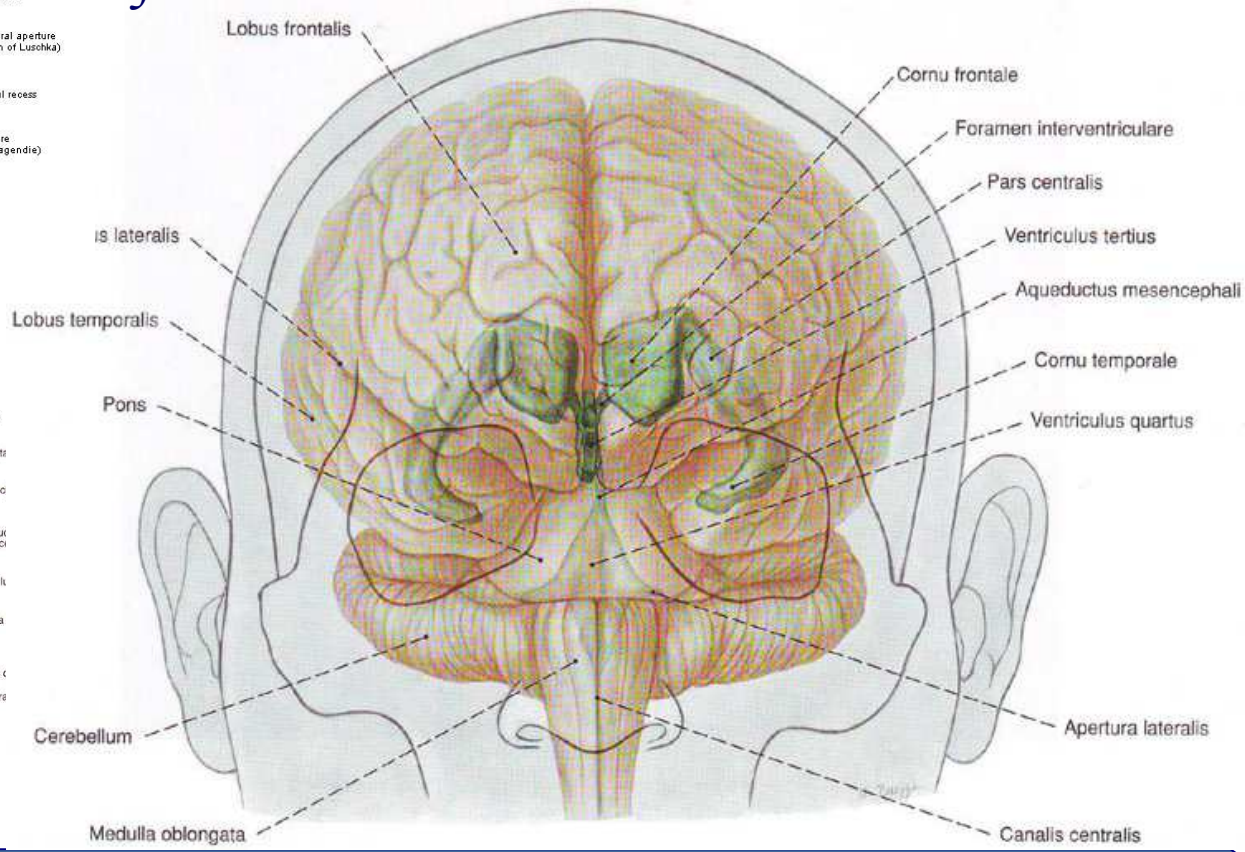

Lateral ventricle

- embryonic origin – *prosencephalon*
- arched-shaped – general shape of hemispheres
- parts:
  - ✓ anterior horn *(cornu)* ~3 cm; triangular shape into the frontal lobe ⇨ *septum pellucidum*
  - ✓ central part ~4 cm; into the parietal lobe; collateral trigone
  - ✓ posterior horn *(cornu)* – 1.2-2 cm; into the occipital lobe ⇨ *calcar avis*
  - ✓ inferior horn *(cornu)* – 3-4 cm; into the temporal lobe ⇨ *hippocampus;* collateral eminence
- composition – cerebrospinal fluid:
  - ✓ *plexus choroideus ventriculi lateralis* – missed in the anterior and posterior horns
- communication with:
  - ✓ third ventricle – interventricular foramina (of *Monro*)

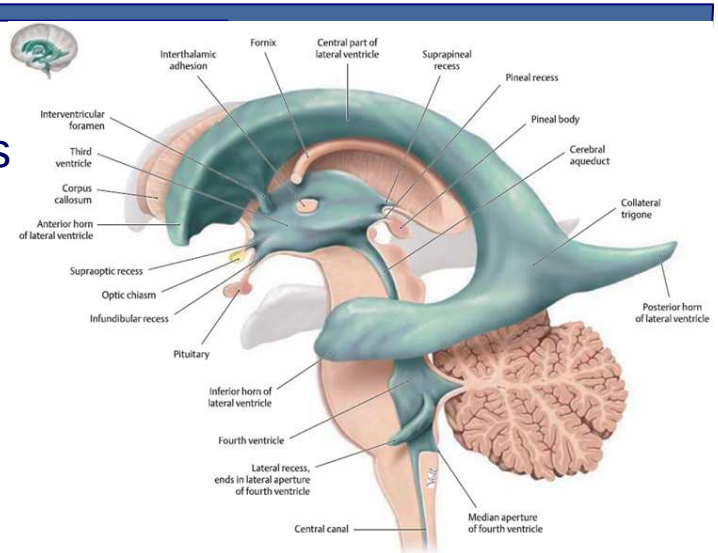

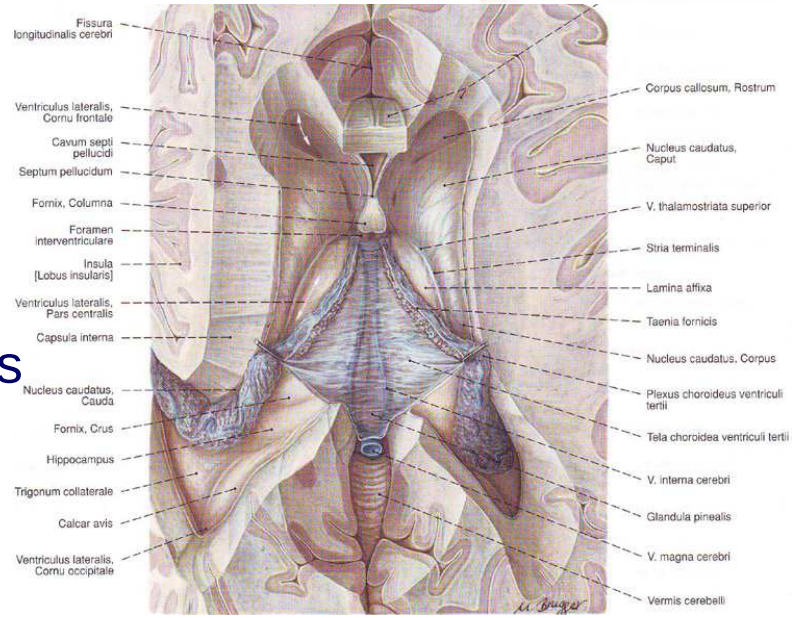

Thank you…